*Early*CDT™-Lung – A Newly Marketed Blood Test To Aid The Early Detection Of Lung Cancer In High-Risk Patients – Enhances The Positive Predictive Power Of Computed Tomography

Richard F. Kucera, M.D., and David West, M.D.
Pulmonary and Critical Care Associates, Greensburg, Pennsylvania

INTRODUCTION

Lung cancer continues to be a vexing problem. Despite attempts to improve survival of lung cancer with treatment and screening programs, overall survival remains dismal. The most promising hope for survival improvement appears to be screening high-risk individuals by low-dose helical (spiral) computed tomography (CT). In fact, in November 2010, the National Lung Screening Trial was stopped after a 20% reduction in lung cancer mortality was reported by annual low-dose helical (spiral) CT screening.[1] This was a very important finding, as it was the first study to show that early detection of lung cancer saves lives.

Despite this recent finding, a 19-20% survival rate remains quite grim. Additionally, annual low-dose helical CT screening is costly, has a high incidence of false positives, and may have radiation-induced hazards. We report a case where a newly-marketed blood test , Oncimmune's *Early*CDT™-Lung, impacted the difficult decision to operate on a patient with a CT-identified pulmonary lesion, which led to the early detection and resection of a stage Ia non-small cell lung cancer.

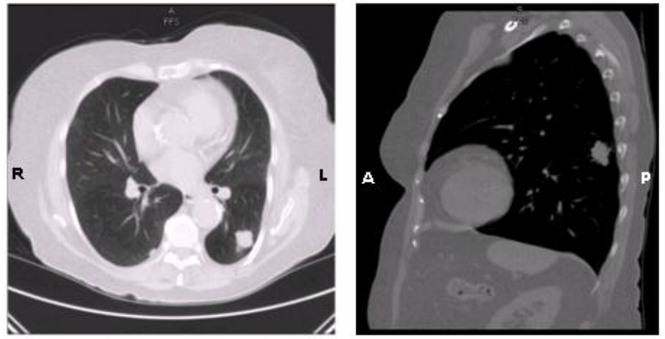

Figure 1. Chest CT showing speculated nodule in the posterior segment of the left lower lobe measuring 2 cm; lesion not present in CT taken 5 years prior. CT/positron emission tomography (PET) showed the nodule to be PET-avid.

CASE PRESENTATION

An 80-year-old woman presented with a complaint of back pain. She had a history of chronic kidney disease, hypertension, gastroesophageal reflux, and a transient ischemic event (TIA). She had a 20 pack/year history of cigarette smoking, long-term exposure to second-hand smoke, and a strong family history of cancer. Physical examination revealed a well-developed female weighing 154 lbs with a blood pressure of 150/79, but was non-revealing for causes of back pain.

A CT of the abdomen was negative for disease, but an incidental speculated nodule in the left lower lung (diameter = 2 cm) and a right pulmonary nodule (diameter = 5 mm) were noted. Upon comparison to a CT of the chest taken five years prior, the right pulmonary nodule and other small nodules were stable; left pulmonary nodule was new (Figure 1). CT/positron emission tomography (PET) revealed the lesion to be PET-avid.

The patient's blood was tested for the presence of autoantibodies (AAbs) to six tumor-associated antigens known to have implications in lung cancer (*Early*CDT-Lung, Oncimmune USA LLC, De Soto, KS).[2-3] The *Early*CDT-Lung blood test showed elevated levels of an autoantibody associated with lung cancer (Table 1).

After complete cardiovascular and pulmonary evaluation, a left lower lobe pulmonary resection was performed. Pathology revealed a 2.5 cm non-small cell lung cancer with all nodes negative (stage Ia/N0/MO). The patient developed a small pneumothorax post-operatively, but otherwise made an uneventful recovery.

Table 1. *Early*CDT-Lung showed an elevated AAb level above cutoff for CAGE, indicating the patient is at high risk of having a lung cancer.

Test	Units	Result	Cutoff
Annexin 1 AAb	RU	<6.3400	6.89
CAGE AAb	**RU**	**4.8272**	**4.05**
GBU4-5 AAb	RU	2.6395	4.28
NY-ESO-1 AAb	RU	<2.9600	3.43
p53 AAb	RU	<4.1000	5.42
SOX2 AAb	RU	<3.3600	3.71

DISCUSSION

When a pulmonary nodule is detected by CT, the decision to recommend an invasive procedure can be difficult. The false positive rate is high, and surgery can be detrimental for patients who are elderly and/or have poor pulmonary and cardiovascular function. In this case, the PET-avid lesion increased the likelihood of malignancy, and the positive *Early*CDT-Lung result provided further evidence.

*Early*CDT-Lung is a new blood test performed by Oncimmune USA LLC that consists of a panel of tumor-associated antigens that when present in the body induce the formation of circulating autoantibodies, which are detected by the ELISA-based test.[2-3] The presence of autoantibodies to tumor antigens correlates highly with the presence of cancer and can predate the visibility of the tumor on imaging.[4]

CONCLUSIONS

- **Preliminary evidence suggests that *Early*CDT-Lung can improve the positive predictive value of CT for correctly predicting diagnosis of malignancy.**
- **In this case, *Early*CDT-Lung was influential in the detection and resection of a very early-stage lung cancer.**

REFERENCES

1. National Lung Screening Trial Research Team. The National Lung Screening Trial: Overview and Study Design. *Radiology*, Jan 2011; 258:243-253.
2. Murray A, et al. Technical validation of an autoantibody test for lung cancer. *Ann Oncol,* 2010; 21:1687-1693.
3. Boyle P, et al. Clinical validation of an autoantibody test for lung cancer. *Ann Oncol,* 2011; 22:383-389.
4. Zhong L, et al. Profiling tumor-associated antibodies for early detection of non-small cell lung cancer. *J Thor Oncol,* 2006;1: 513–519.

American Thoracic Society's 2011 International Conference; Denver, Colorado; May 13-18, 2011